


Cat No: CIN483 – Cervical intraepithelial neoplasia tissue array, set 3

Lot#	Cores	Size	Cut	Format	QA/QC
CIN48301	48	1.5mm	4um	6X8	H&E, IHC anti-Cytokeratin



Recommended applications: For Research use only. RNA or protein analyses using IHC or ISH designed for cervical intraepithelial neoplasia tissue profiling.

Description: Cervical intraepithelial neoplasia tissue array, set 3, non-overlapping with CIN481 or CIN482 covering the whole spectrum from normal, CIN I, CIN II, CINII and invasive cancer, 48 cases (1.5mm).

All the tissues were from surgical resection. They were fixed in 10% neutral buffered formalin for 24 hours and processed using identical SOPs. Sections were picked onto Superfrost Plus or APES coated Superfrost slides. They can be stored for use at 4C for up to six months from the date of shipment. **There may be 5 to 10% of tissue core loss.**

Array Position	Sex	Age	Anatomic Site	Pathology	Grade	Stage
A01	F	40	Cervix	Chronic cervicitis	null	null
A02	F	39	Cervix	Chronic cervicitis	null	null
A03	F	43	Cervix	Chronic cervicitis	null	null
A04	F	52	Cervix	Chronic cervicitis	null	null
A05	F	40	Cervix	Chronic cervicitis	null	null
A06	F	44	Cervix	Chronic cervicitis	null	null
A07	F	31	Cervix	CIN with early invasive cancer	III	null
A08	F	39	Cervix	CIN	I	null
B01	F	46	Cervix	CIN	I	null
B02	F	48	Cervix	CIN	I	null
B03	F	42	Cervix	CIN	I	null
B04	F	68	Cervix	CIN	I	null
B05	F	30	Cervix	CIN with early invasive cancer	III	null
B06	F	48	Cervix	CIN	II	null
B07	F	52	Cervix	CIN	II	null
B08	F	44	Cervix	CIN	I	null
C01	F	45	Cervix	CIN	I~II	null
C02	F	25	Cervix	CIN	I~II	null
C03	F	49	Cervix	CIN	I	null
C04	F	57	Cervix	CIN with early invasive cancer	III	null
C05	F	36	Cervix	CIN	I~II	null
C06	F	48	Cervix	CIN	I~II	null
C07	F	43	Cervix	CIN	I	null
C08	F	50	Cervix	CIN	I	null
D01	F	45	Cervix	CIN	I	null
D02	F	45	Cervix	CIN	I	null
D03	F	29	Cervix	CIN	II	null
D04	F	50	Cervix	CIN	II~III	null
D05	F	25	Cervix	CIN	II	null
D06	F	27	Cervix	CIN	II	null
D07	F	41	Cervix	CIN with early invasive cancer	III	null
D08	F	44	Cervix	CIN	II	null
E01	F	43	Cervix	CIN	I~II	null
E02	F	73	Cervix	CIN with early invasive cancer	III	null
E03	F	56	Cervix	CIN with early invasive cancer	III	null
E04	F	48	Cervix	CIN with early invasive cancer	III	null
E05	F	39	Cervix	CIN with early invasive cancer	III	null
E06	F	50	Cervix	CIN	III	null
E07	F	47	Cervix	CIN with early invasive cancer	III	null

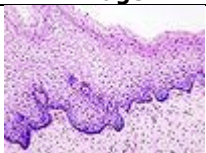
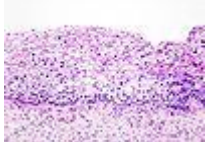
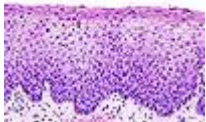
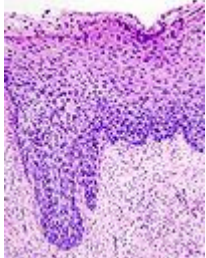
Advancing Biomedical Science Through Tissue Arrays

E08	F	47	Cervix	CIN with early invasive cancer	III	null
F01	F	58	Cervix	CIN	III	null
F02	F	49	Cervix	CIN with early invasive cancer	III	null
F03	F	46	Cervix	CIN	III	null
F04	F	42	Cervix	CIN with early invasive cancer	III	null
F05	F	40	Cervix	Squamous cell carcinoma	II	null
F06	F	53	Cervix	Squamous cell carcinoma	III	null
F07	F	64	Cervix	Squamous cell carcinoma	II	null
F08	F	70	Cervix	Squamous cell carcinoma	II	null

Notes: Bake at 60C for ~60 minutes before use. If antigen retrieving is needed, it is important to avoid **direct-boiling and high pH or high strength** antigen retrieving buffer. For availability of complimentary IHC data, please contact us at info@pantomics.com.

Certified by: Langxing Pan, M.D.

Cervical intraepithelial neoplasia grading:

Histology Grade	Description	Image
-	Normal cervical epithelium	
CIN 1 (Grade I)	The least risky type, represents only mild dysplasia, or abnormal cell growth. It is confined to the basal 1/3 of the epithelium. This corresponds to infection with HPV, and typically will be cleared by immune response in a year or so, though can take several years to clear.	
CIN 2/3	Formerly subdivided into CIN2 and CIN3.	
CIN 2 (Grade II)	Moderate dysplasia confined to the basal 2/3 of the epithelium	
CIN 3 (Grade III)	Severe dysplasia that spans more than 2/3 of the epithelium, and may involve the full thickness. This lesion may sometimes also be referred to as cervical carcinoma in situ.	



TNM Classification: Cervical carcinoma

T- Primary tumor

TX - Primary tumor cannot be assessed

TO - No evidence of primary tumor

Tis - Carcinoma in situ

T1 - Cervical carcinoma confined to uterus (extension to corpus should be disregarded)

T1a Invasive carcinoma diagnosed only by microscopy. Stromal invasion with a maximum depth of 5.0mm measured from the base of the epithelium and a horizontal spread of 7.0mm or less. Vascular space involvement, venous or lymphatic, does not affect classification.

T1a1 Measured stromal invasion 3.0mm or less in depth and 7.0mm or less in horizontal Spread.

T1a2 Measured stromal invasion more than 3.0mm and not more than 5.0mm with a horizontal spread 7.0mm or less.

T1b Clinically visible lesion confined to the cervix or microscopic lesion greater than T1a/IA2.

T1 b1 Clinically visible lesion 4.0cm or less in greatest dimension.

T1b2 Clinically visible lesion more than 4.0cm in greatest dimension.

T2 - Cervical carcinoma invades beyond uterus but not to pelvic wall or to lower third of vagina

T2a Tumor without parametrial invasion

T2b Tumor with parametrial invasion

T3 - Tumor extends to pelvic wall and/or involves lower third of vagina, and/or causes hydronephrosis or non-functioning kidney

T3a Tumor involves lower third of vagina, no extension to pelvic wall

T3b Tumor extends to pelvic wall and/or causes hydronephrosis or non-functioning kidney

T4 - Tumor invades mucosa of bladder or rectum, and/or extends beyond true pelvis (bullous edema is not sufficient to classify a tumor as T4)

N - Regional lymph nodes

NX - Regional lymph nodes cannot be assessed

NO - No regional lymph node metastasis

N1 - Regional lymph node metastasis

M - Distant metastasis